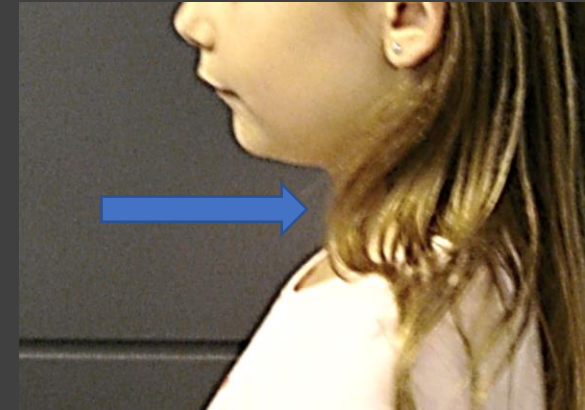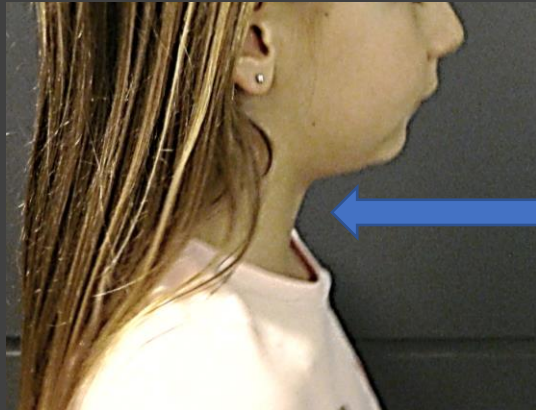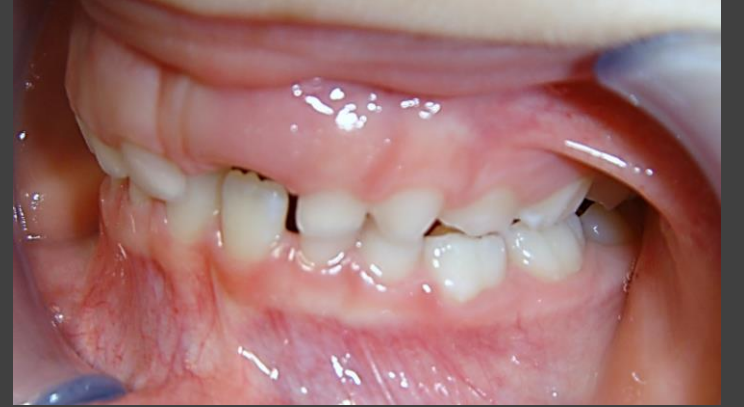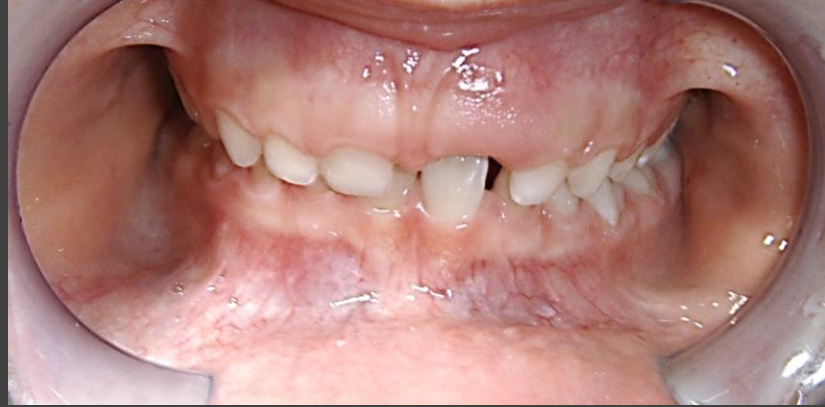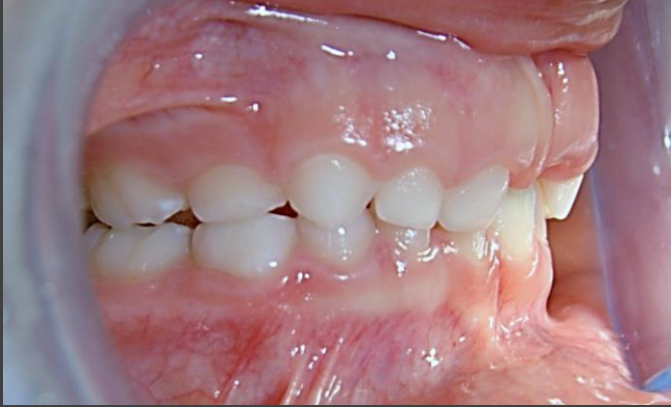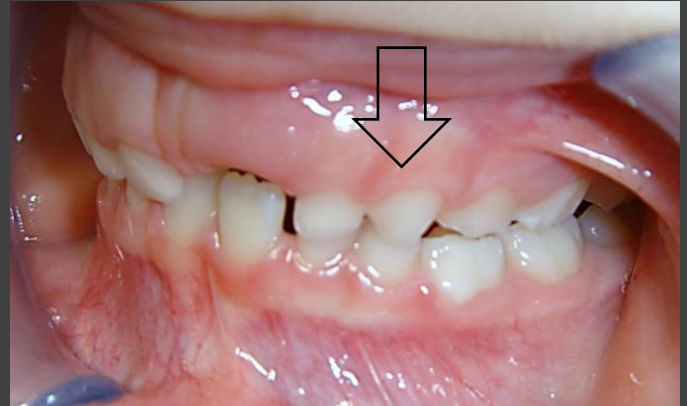
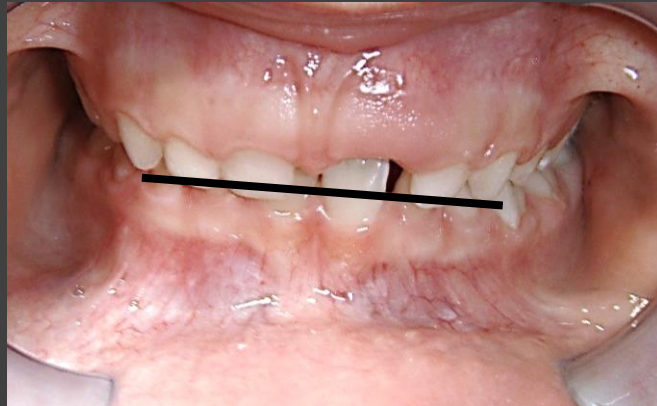
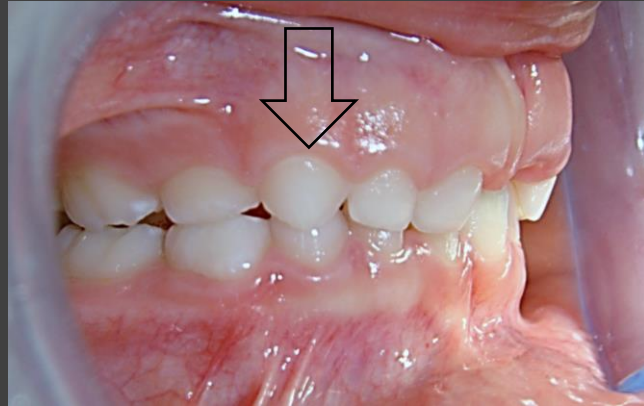


START USING FROGGY MOUTH



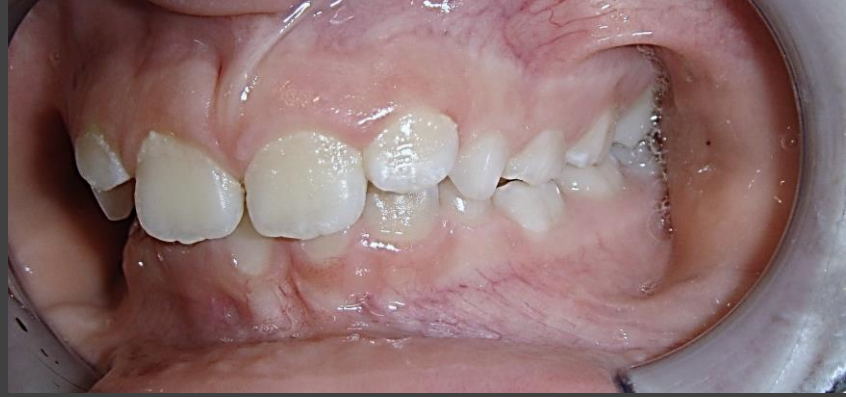
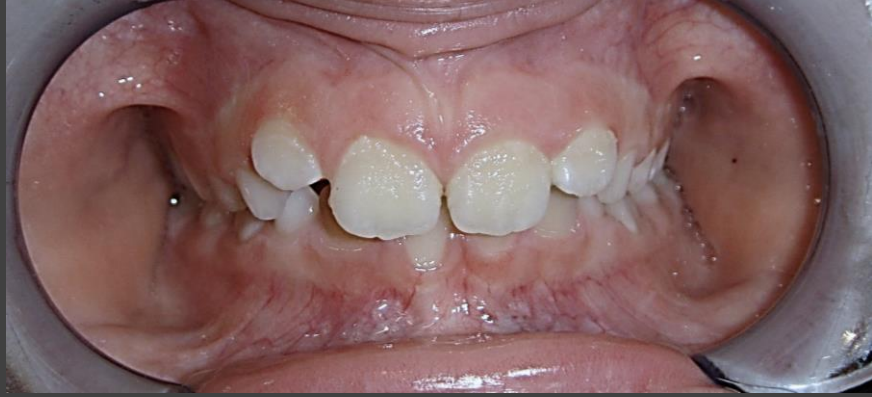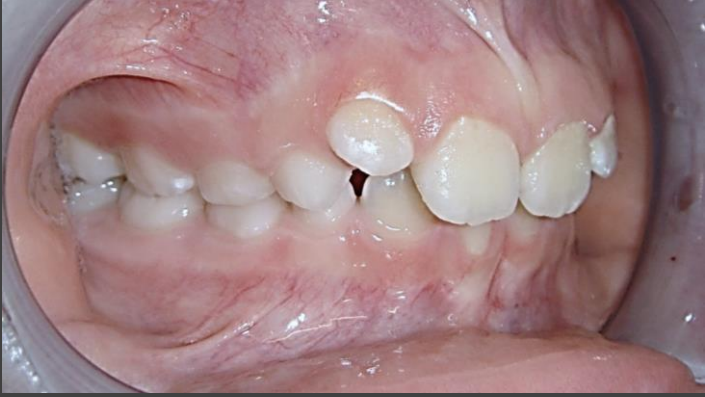START USING FROGGY MOUTH



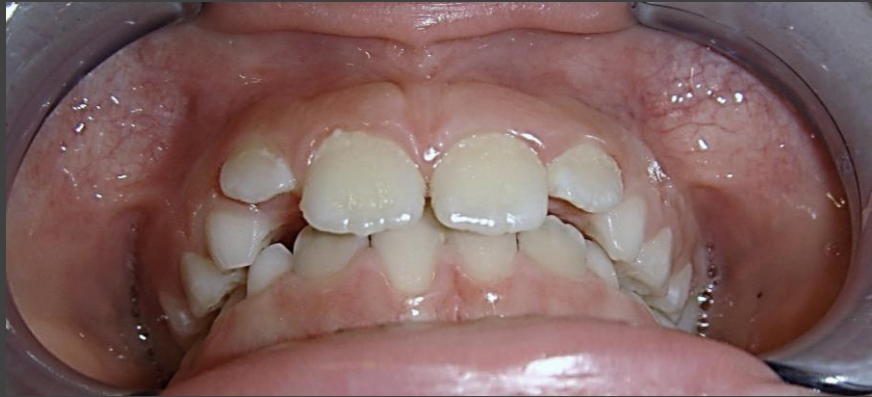DR. PIETRO MANZINI
ORTHODONTIC SPECIALIST

DR. PIETRO MANZINI
ORTHODONTIC SPECIALIST






8 MONTHS LATER

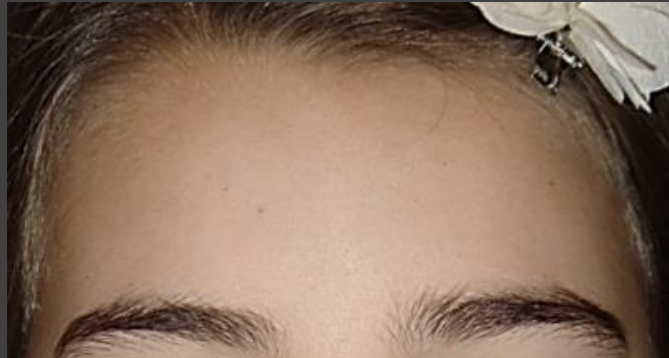

DR. PIETRO MANZINI
ORTHODONTIC SPECIALIST

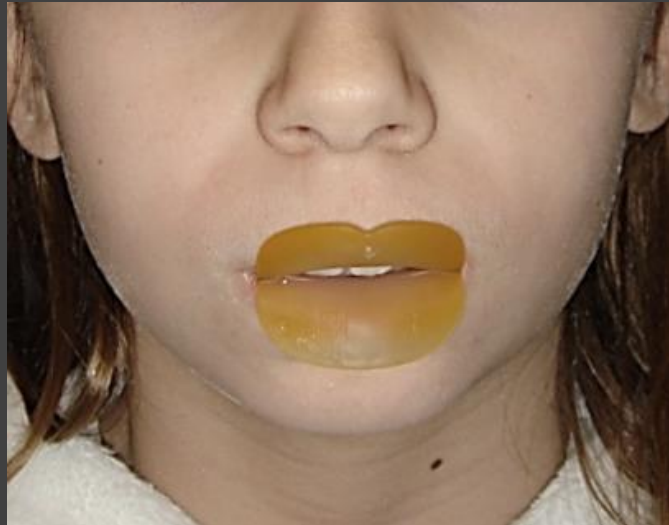DR. PIETRO MANZINI
ORTHODONTIC SPECIALIST



DR. PIETRO MANZINI
ORTHODONTIC SPECIALIST




NO AMUCHINA



8 MONTHS LATER

DR. PIETRO MANZINI
ORTHODONTIC SPECIALIST

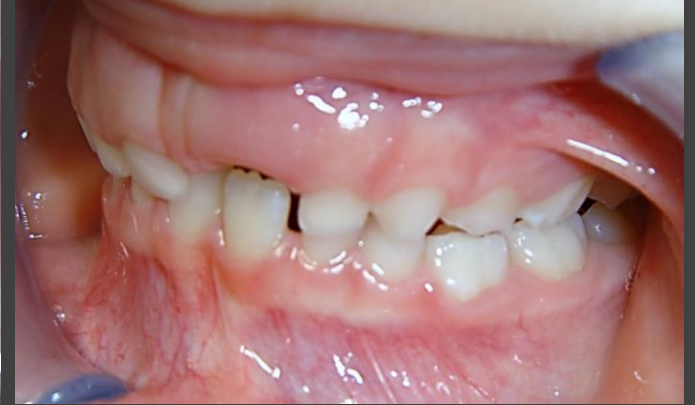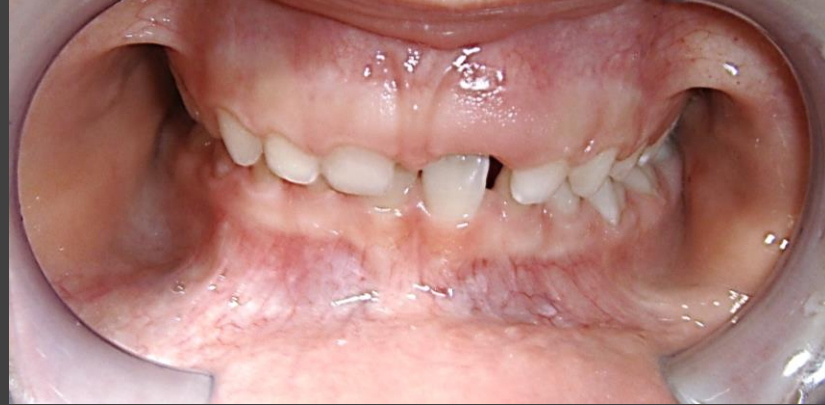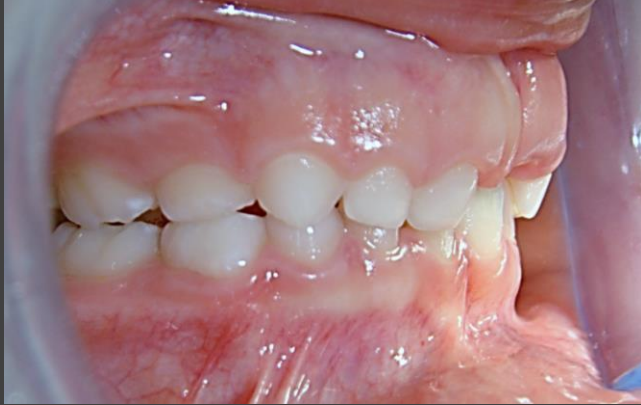DR. PIETRO MANZINI
ORTHODONTIC SPECIALIST



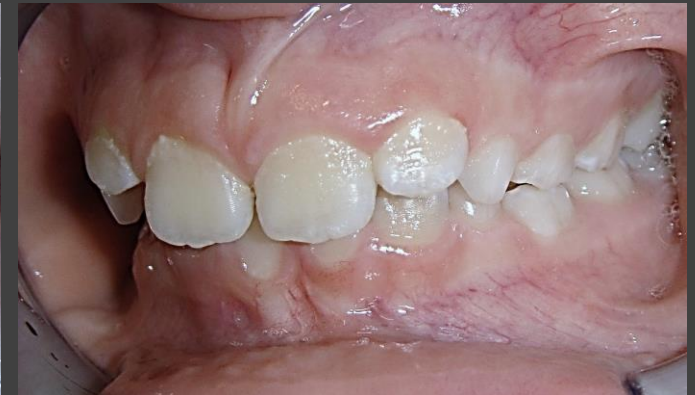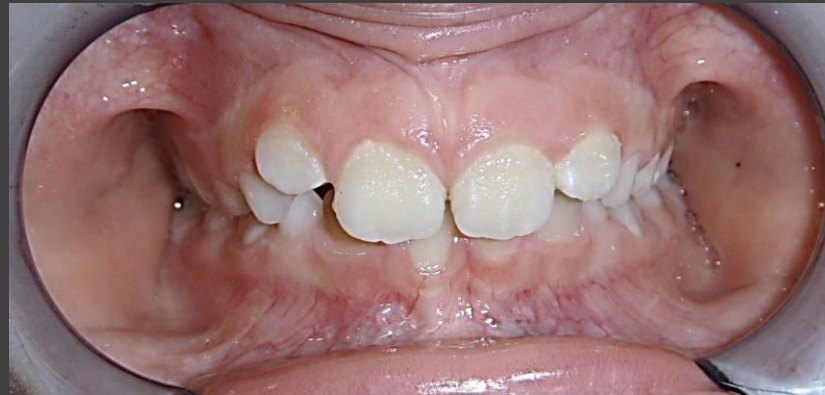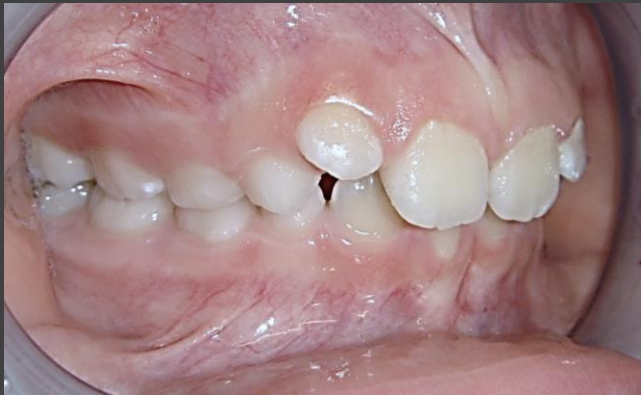DR. PIETRO MANZINI
ORTHODONTIC SPECIALIST

8 MONTHS LATER

DR. PIETRO MANZINI
ORTHODONTIC SPECIALIST



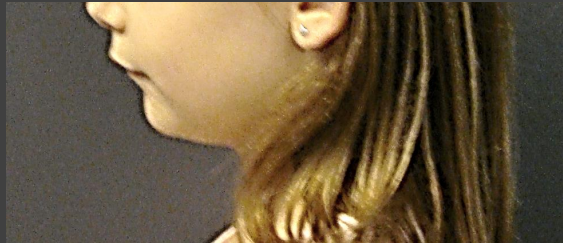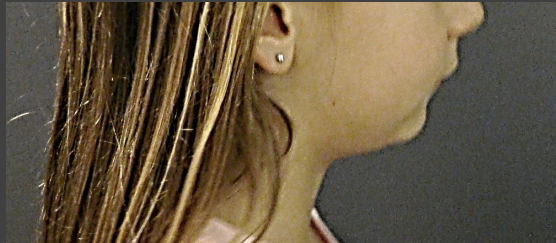START USING FROGGY MOUTH



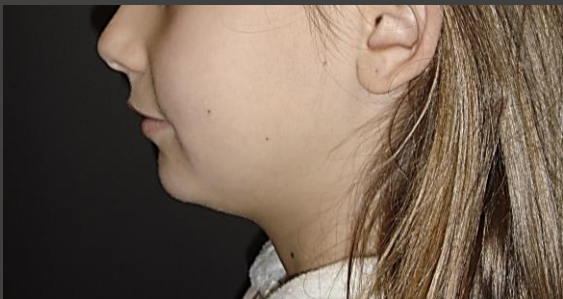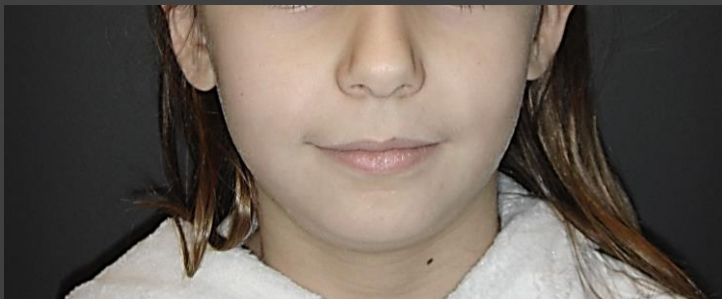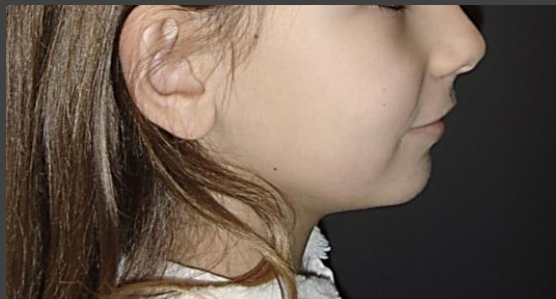8 MONTHS LATER

DR. PIETRO MANZINI
ORTHODONTIC SPECIALIST

DR. PIETRO MANZINI
ORTHODONTIC SPECIALIST




START USING FROGGY MOUTH



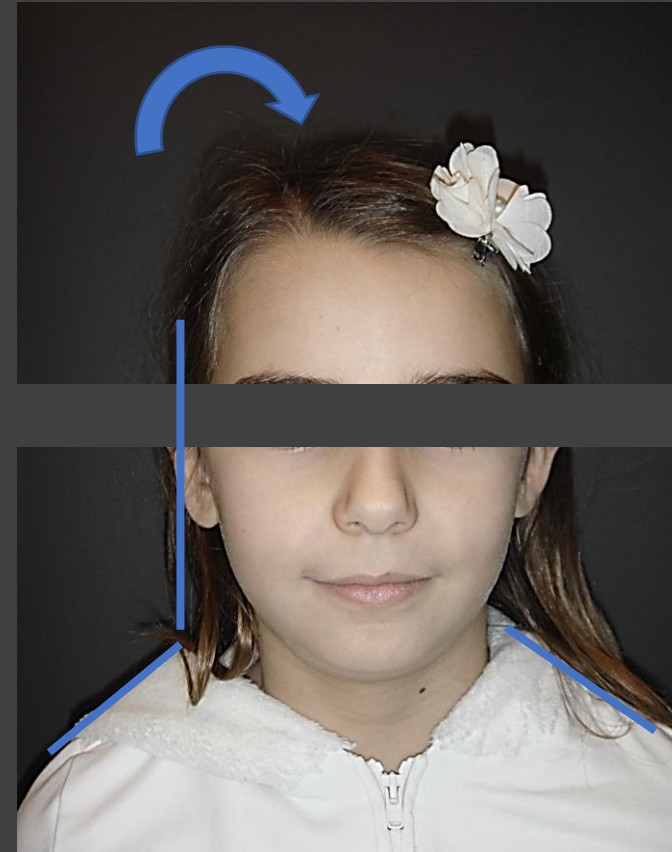8 MONTHS LATER

DR. PIETRO MANZINI
ORTHODONTIC SPECIALIST

DR. PIETRO MANZINI
ORTHODONTIC SPECIALIST



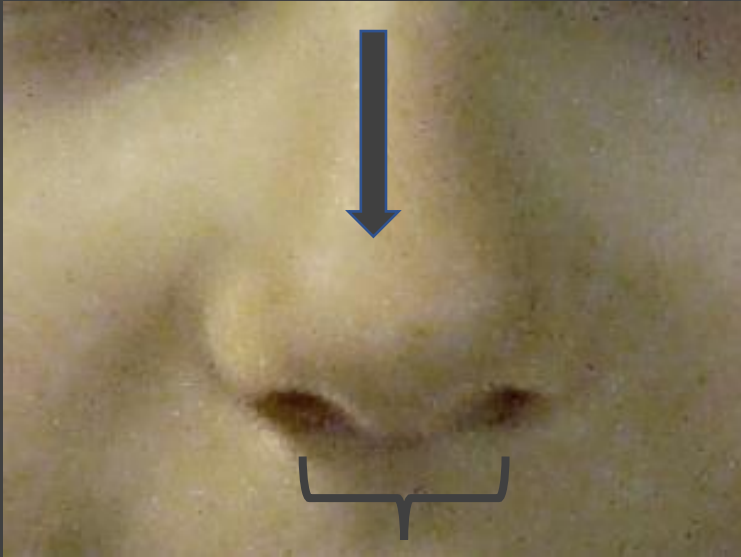
START USING FROGGY MOUTH



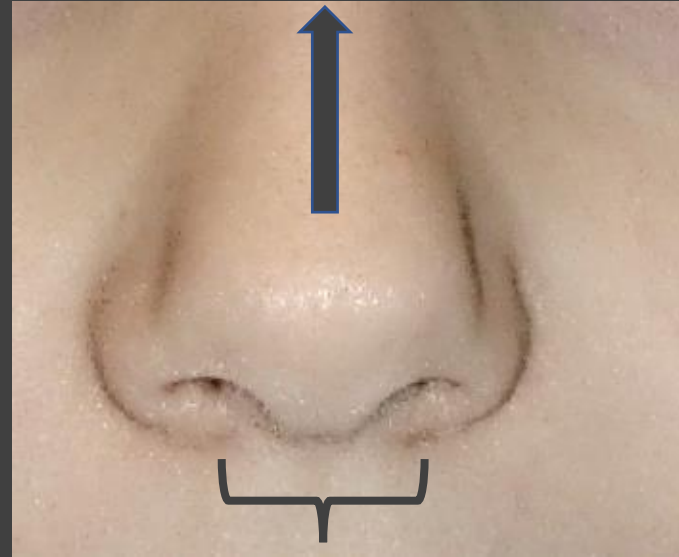
8 MONTHS LATER

DR. PIETRO MANZINI
ORTHODONTIC SPECIALIST

DR. PIETRO MANZINI
ORTHODONTIC SPECIALIST



START USING FROGGY MOUTH



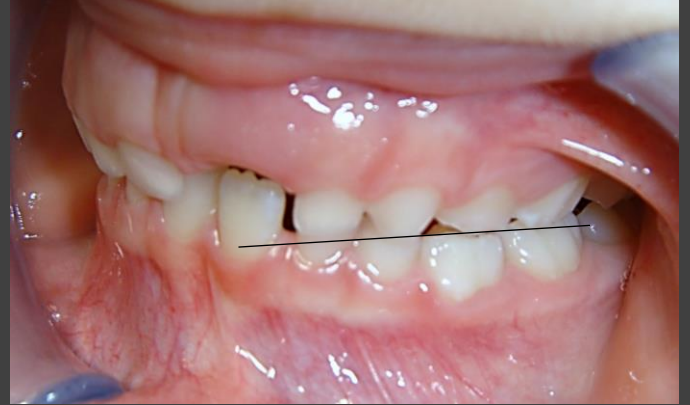
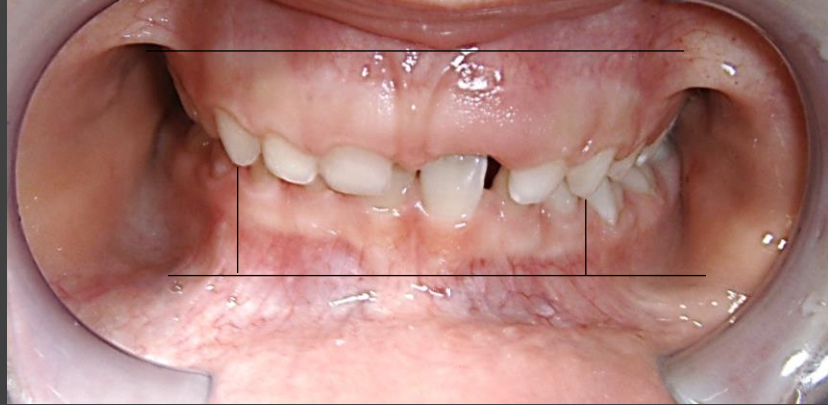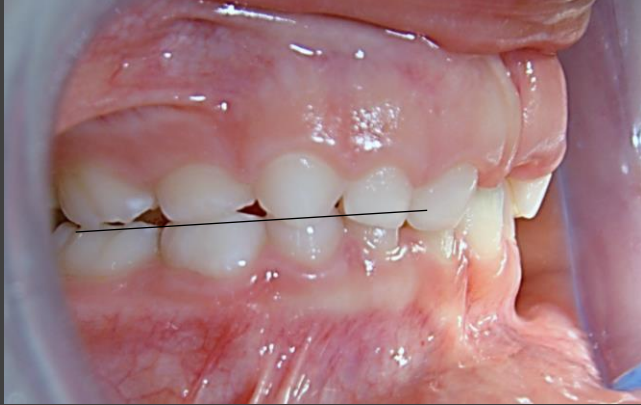
8 MONTHS LATER

DR. PIETRO MANZINI
ORTHODONTIC SPECIALIST

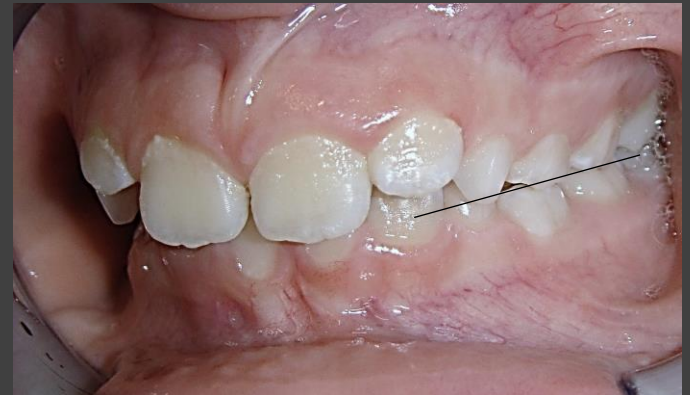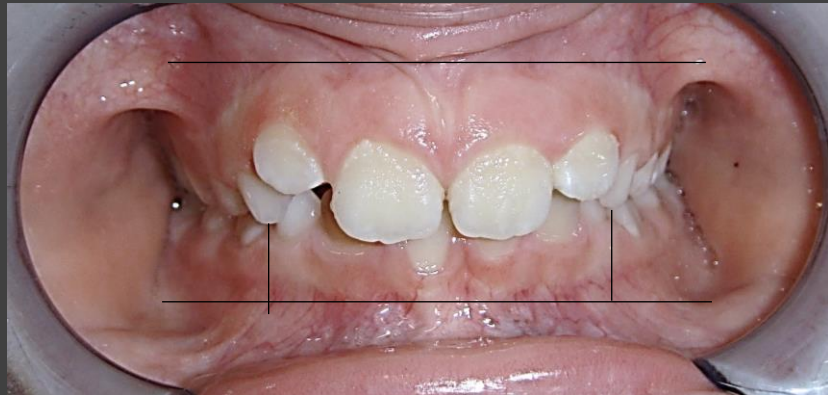

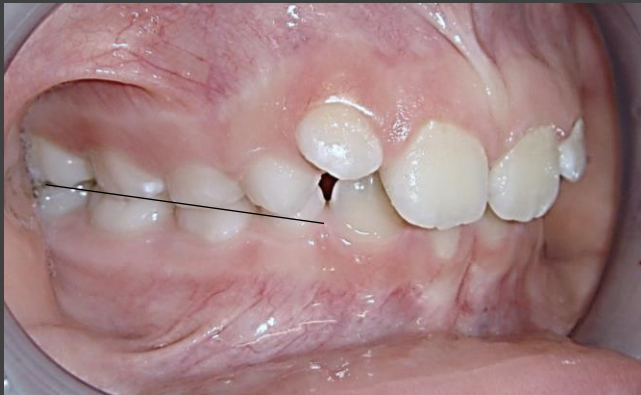
DR. PIETRO MANZINI
ORTHODONTIC SPECIALIST


DR. PIETRO MANZINI
ORTHODONTIC SPECIALIST



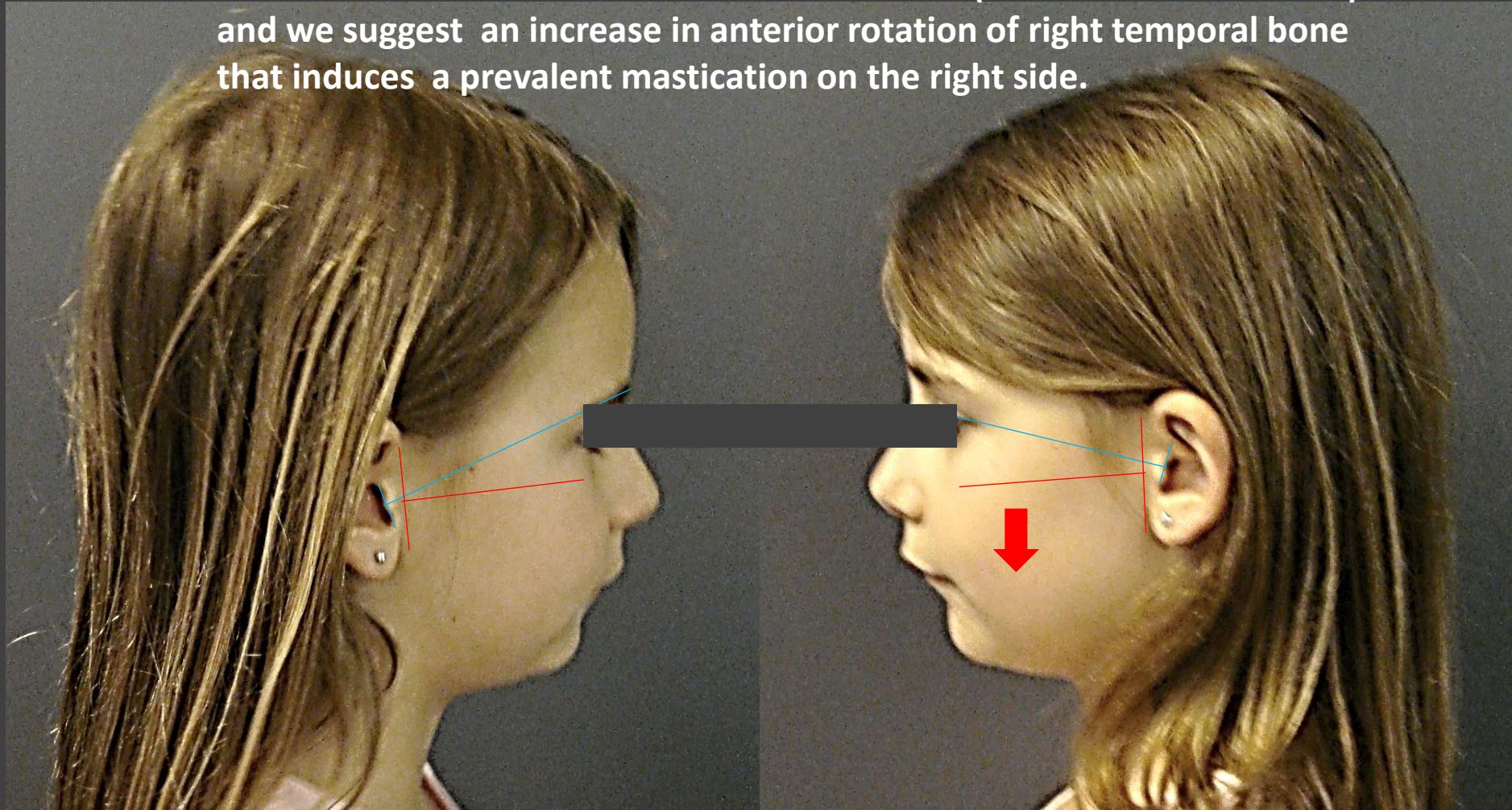
START USING FROGGY MOUTH



8 MONTHS LATER





The ears axes are further down on the left side (in relation to the orbit) and we suggest an increase in anterior rotation of right temporal bone that induces a prevalent mastication on the right side.



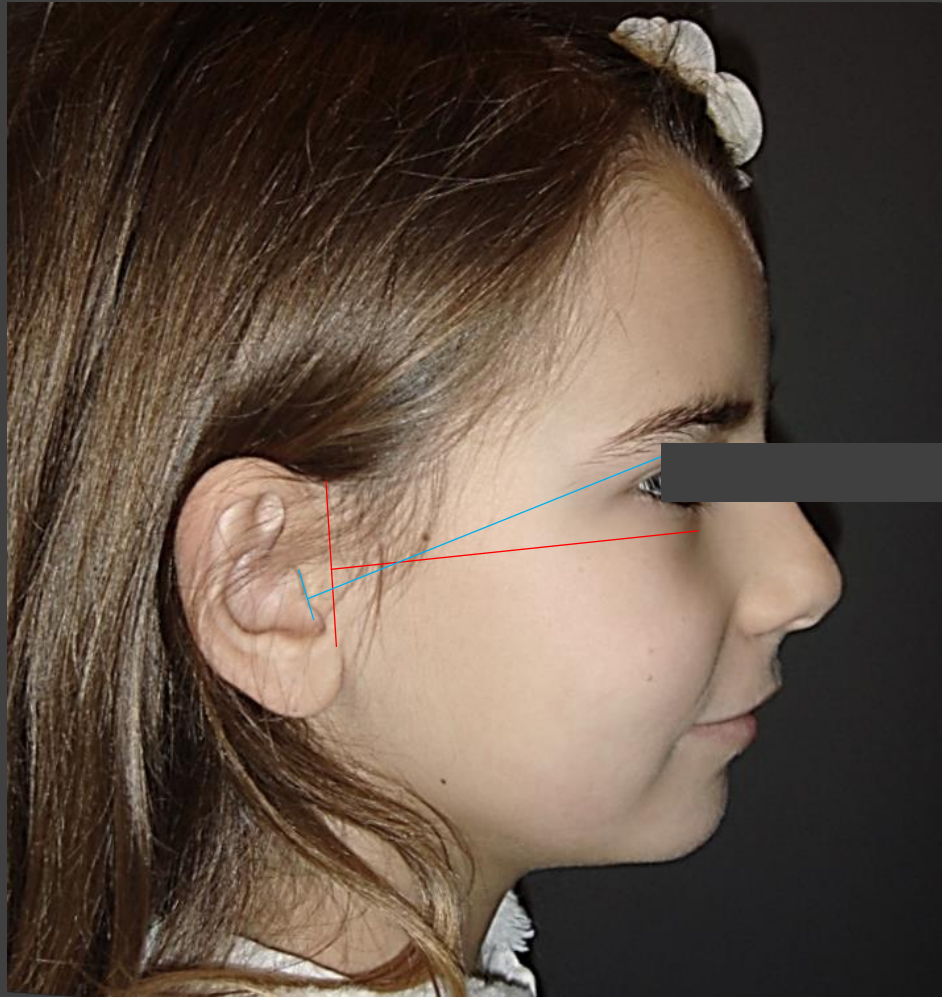
DR. PIETRO MANZINI
ORTHODONTIC SPECIALIST

DR. PIETRO MANZINI
ORTHODONTIC SPECIALIST

START USING FROGGY MOUTH

-  Sphenoid bone that induces an increase in rotation of the squamous part of temporal bone.
-  Occipital bone that induces the orientation of petrous part of temporal bone

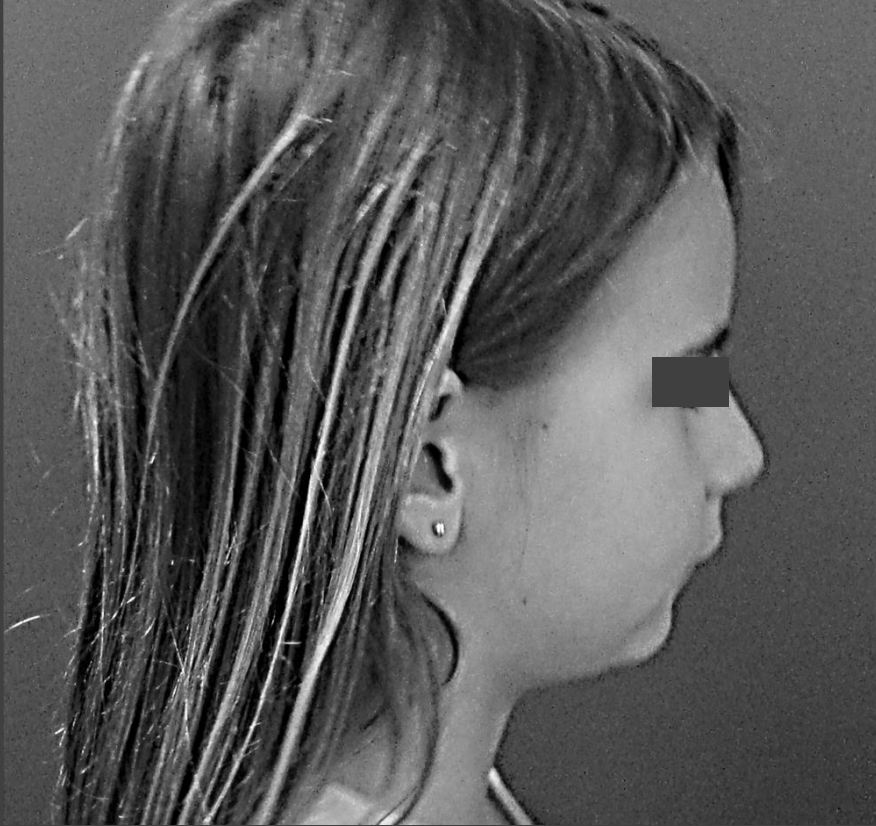DR. PIETRO MANZINI
ORTHODONTIC SPECIALIST



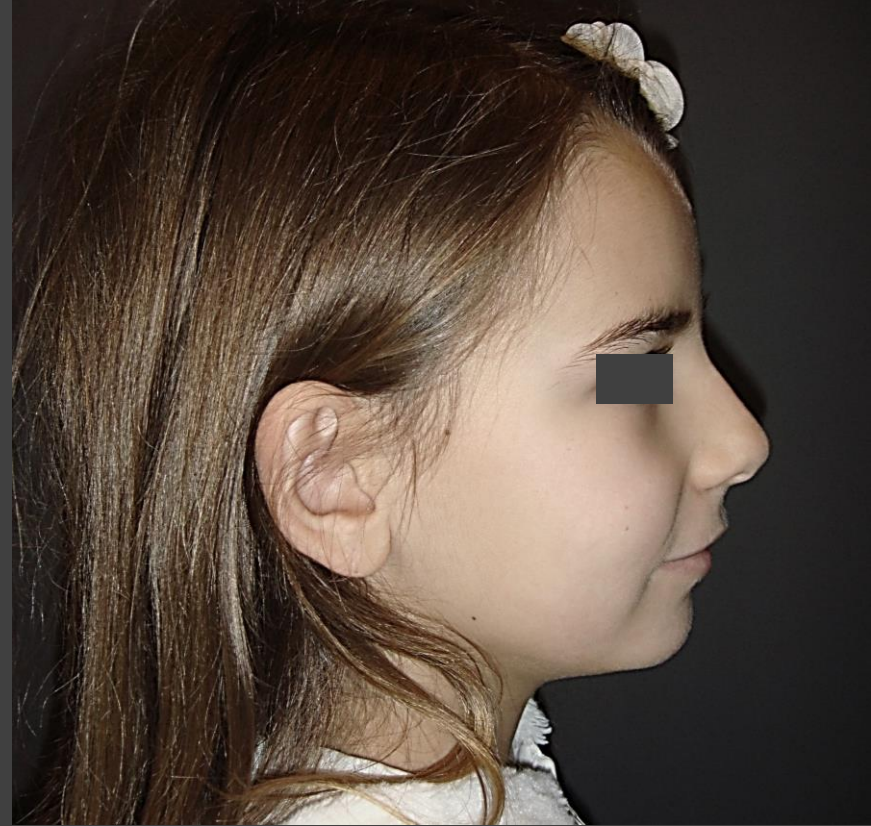
DR. PIETRO MANZINI
ORTHODONTIC SPECIALIST

8 MONTHS LATER

DR. PIETRO MANZINI
ORTHODONTIC SPECIALIST



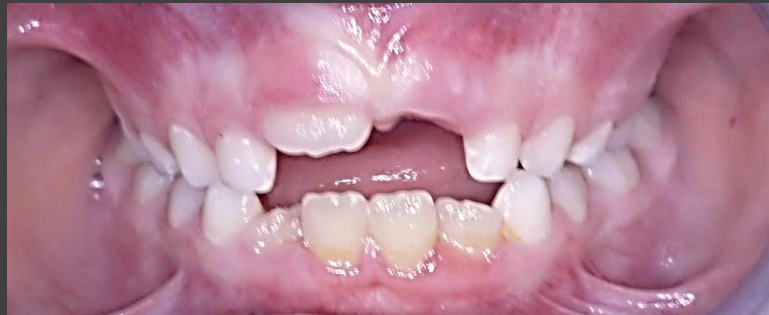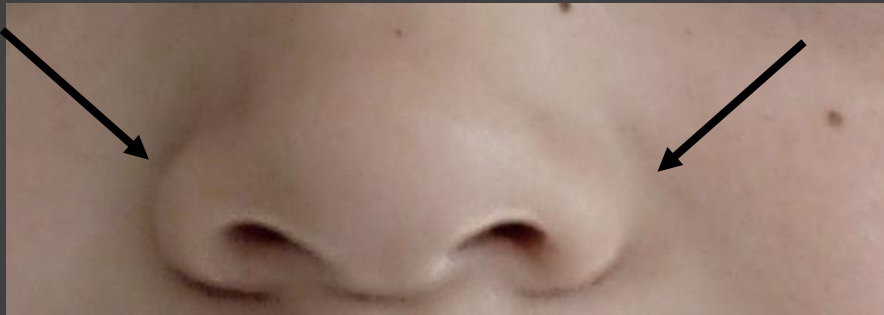START USING FROGGY MOUTH



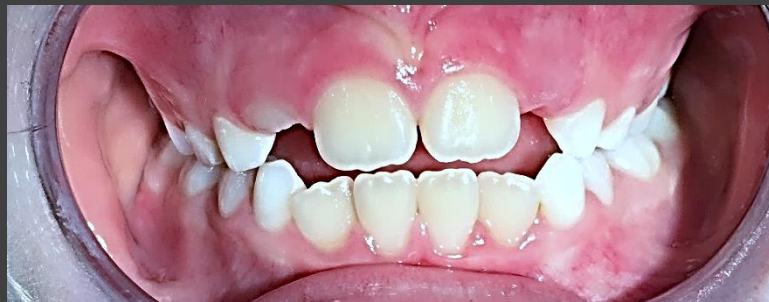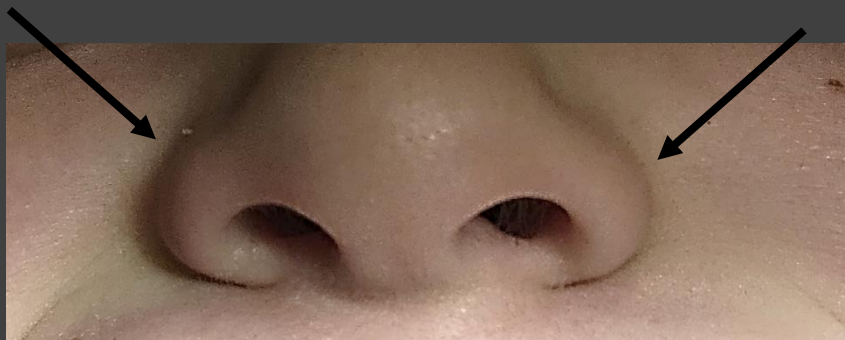8 MONTHS LATER

DR. PIETRO MANZINI
ORTHODONTIC SPECIALIST

DR. PIETRO MANZINI
ORTHODONTIC SPECIALIST

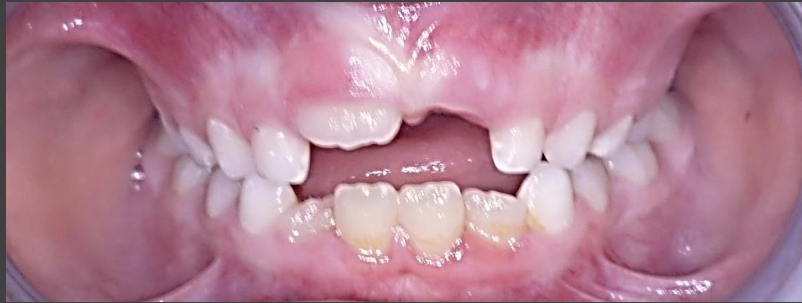

START USING FROGGY MOUTH

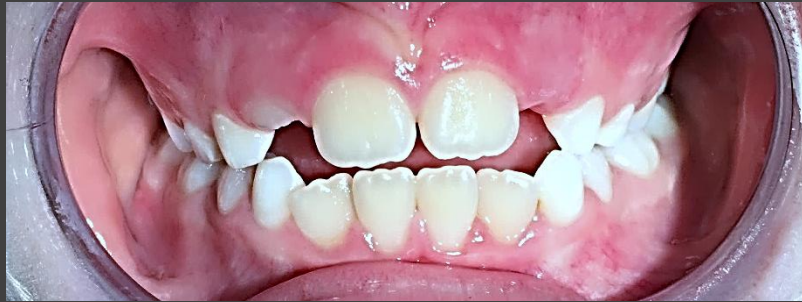

8 MONTHS LATER

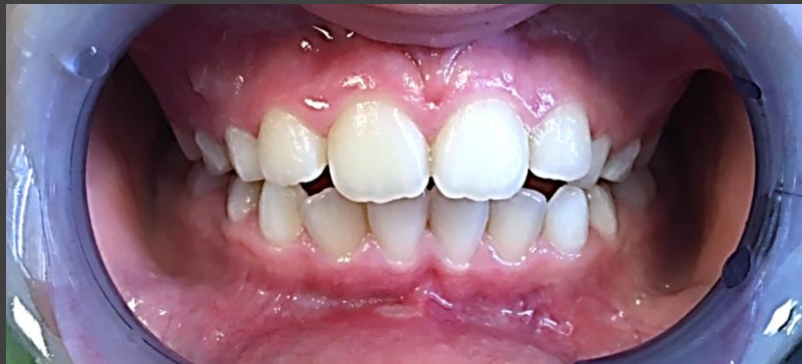DR. PIETRO MANZINI
ORTHODONTIC SPECIALIST



START USING FROGGY MOUTH



8 MONTHS LATER



16 MONTHS LATER—END TREATMENT