

# Froggy mouth: a new myofunctional approach towards atypical swallowing



S. Di Vecchio\*, P. Manzini\*\*,  
E.Candida\*\*\*, Gargari  
M.\*\*\*\*

\*Department of Dentistry Hospital San  
Pietro F.B.F., Rome, Italy

\*\*Department of Maxillofacial Unit,  
Neuroscience, Carlo Poma Hospital,  
Mantova, Italy

\*\*\*Private practice Rome, Italy

\*\*\*\*Department of Clinical Sciences and  
Translational Medicine, University of Rome  
"Tor Vergata", Rome, Italy

## Abstract

**Introduction** Atypical swallowing has a high incidence in adult and child populations. The treatment of the latter is generally achieved by the adoption of orthodontic appliances in conjunction with speech therapy. The aim of this article is to describe the clinical protocol of Froggy Mouth, an innovative myofunctional appliance designed to correct the atypical swallowing.

**Materials and method** The Froggy Mouth appliance has been tested by the authors Di Vecchio at the Orthognatodontics department of Fatebenefratelli San Pietro Hospital in Rome, Italy, and by Manzini at the Orthodontics department of Carlo Poma Hospital in Mantova, Italy. This article will illustrate the clinical protocol of the appliance with therapeutic indications, clinical phases, instruction and patients and parents motivation and follow-up results.

**Results** Froggy Mouth has proven effective in the correction of atypical swallowing, from both the clinical and the functional standpoints. The fastest and most predictable results were obtained in patients during their physiological developmental age. This appliance, compared to the traditional logopaedic therapy, requires less commitment in terms of time for the patient (only 15 minutes per day), with more predictable and durable results over time.

**Conclusions** The clinical evidences indicate that the Froggy Mouth is effective in the myofunctional correction of the atypical swallowing mechanism, providing the clinician a new therapeutic approach for neuromuscular re-training of atypical deglutition and dysfunctional deglutition in patients during their growth phase. However, further scientific evidences are needed to support the results of this investigation.

**KEYWORD** Atypical swallowing, Froggy Mouth, Myofunctional appliance, Open bite, Orthodontics, Speech therapy.

## Introduction

Atypical swallowing is a myofunctional problem, characterised by an altered lingual posture during swallowing. Primary infantile deglutition develops around the 12th week of intrauterine life and it is characterised by a forward tongue posture [Bernandi et al., 2013] and contraction of the perioral muscles [Tecco et al., 2015] (orbicular and buccinator), leading to a higher negative pressure in the oral cavity. In normal conditions, around the age of 3 and with the development of alternate unilateral mastication [Mummolo et al., 2014], the infantile deglutition pattern changes into a so-called mature deglutition pattern [Condò et al., 2012].

During adult or mature swallowing, dental arches are in contact and tongue is elevated, resting in the posterior-superior part of the palatine vault [Suàrez et al., 2014]. During this phase the tongue pressure stimulates the anteroposterior and transversal growth of the maxilla [Eichenberger et al., 2014; Mummolo et al., 2014]. If transition from the infantile to the adult swallowing does not take place, the former triggers a pathological mechanism, defined as atypical swallowing [Giuca et al., 2008].

The aetiology is multifactorial.

- Altered lifestyle such as prolonged bottle feeding, late weaning, consistency of food (lack of solid food).
- Bad habits such as finger or dummy sucking, onychophagy, labial interposition.
- Respiratory problems such as oral breathing, adenoid hypertrophy, tonsillar hypertrophy, rhinitis, bronchial asthma.
- Congenital oral anomalies (short lingual frenulum or ankyloglossy).

Atypical deglutition is frequently correlated with the following.

- Dental malocclusions [Tecco et al., 2014]: proclined maxillary anteriors, increased overjet, openbite, flaring and spaced dentition.
- Skeletal malocclusions [Tecco et al., 2011]: sagittal and transversal discrepancies with a narrow and protruded maxillary arch, mandibular retroposition.

The high prevalence of malocclusions related to atypical swallowing makes this a subject of strong interest in scientific

researches. Because of the multifactorial aetiopathogenesis, high incidence and the correlation with dento-skeletal malocclusions, this topic is not only very interesting for clinicians, but is also strongly debated among healthcare providers. A literature review on this subject confirms that orthodontic treatment alone is not sufficient to solve the problem in patients with atypical swallowing. This requires a multidisciplinary therapy, orthodontic and myofunctional approach, to ensure optimal and long-lasting results [Maspero et al., 2014].

To obtain an adequate myofunctional correction [Mummolo et al., 2014] of atypical swallowing has been treated with appliances such as palatal tongue crib, fixed or removable, the Tucat pearl or speech therapy exercises, requiring a high compliance from the patient, and giving unpredictable and unstable results.

Eric Kandel, Nobel-prize winner in 2000, in his research on the physiological basis of memory storage in neurons has proved that new information is acquired and stored promptly, because the memory cerebral systems are easily modifiable. His studies have proven that when working on subconscious levels it is important not just the duration of treatment but also consistency. Synaptic connections in various brain circuits can be reinforced or slowed down by the engrammatic mechanism and mnemonic traces formed during the learning process and experience, determining in this way definitive biochemical and structural changes [Kandel, 2007].

The learning process occurs through:

- Voluntary pathway, with the stimulation of cortical zones causing synaptic excitation only;
- Involuntary pathway, with modification of synapses structure and increase in their numeric value (permanent stabilisation of new acquisitions); here stimulation origins from the subcortical region, in which automatism are developed.

Following Kandel's research, Patric Fellus (expert in Dentofacial Orthopaedics) designed the Froggy Mouth appliance, which triggers the involuntary pathway, inhibiting bilabial contact and eliminating negative pressure inside oral cavity, enabling the tongue to protrude and retract through styloglossus muscle contraction, thus achieving proper deglutition. Fellus states that the attention of the patient should not be focused on tongue tip, as it usually happens during myofunctional therapy, but on the posterior portion of the tongue. The patient, engaged in tongue tip elevation trying to reach the retroincisal papilla, triggers a lower position of the posterior portion of the tongue, inhibiting elevation of the posterior portion of the tongue by styloglossus muscle action, which would consequently place the tongue tip in its physiological position [Fellus, 2006; Fellus, 2014; Fellus, 2016; Ortu et al., 2016].

The aim of this article is to describe the clinical protocol of Froggy Mouth, an innovative and simple myofunctional appliance used in order to solve atypical swallowing and to allow myofunctional correction of altered tongue position.



FIG. 1 Froggy Mouth is a small removable appliance.

Benefits and limits of this appliance will be confronted with the traditional logopaedic therapy and other appliances traditionally used for the resolution of this condition.

**Materials and methods**

The Froggy Mouth appliance has been tested in 370 patients at the Orthognatodontics Department of Fatebenefratelli San Pietro Hospital in Rome and at the Orthodontics department of Carlo Poma Hospital in Mantova (Italy).

Froggy Mouth is a small removable appliance made of a flexible thermoplastic elastomer, without latex or phthalates. It is available in 3 sizes of different colour orthoboxes S (Blue), M (red) and L (Violet) (Fig. 1). The appliance has a small stamped letter in the inferior portion and a dot in the superior portion. In order to choose the right size, the appliance has a specific dedicated caliber. The Froggy Mouth should be positioned between the lips and the teeth leaving about 2 mm from the labial commissure on both sides.

The Froggy Mouth should be used 15 minutes every day (in order to activate the neural circuits that generate the automatic movements controlled by the trigeminal nerve) always during a playful activity (in order to activate the limbic system that facilitates and accelerates the learning process) [Kandel, 2007]: preferably watching TV, while playing videogames or using the computer. The protocol requires to maintain a correct head position parallel to the floor.

Indications of Froggy Mouth are: atypical sawllowing, tongue interposition between dental arches, anterior and posterior openbite, trasversal contraction, anterior or posterior crossbite, increased overjet, proclined front teeth, deep bite, mandibular protrusion, dyslalia, bruxism, posture alteration, oral breathing and adenoid disorders,snoring, drooling.

Before delivery of the appliance, the following was required:

- 1) Filling of the Clinical record (Fig. 2-4).

This ad hoc Clinical record was created in collaboration

**Clinical record**

Date \_\_\_/\_\_\_/\_\_\_

Operator \_\_\_\_\_

Surname \_\_\_\_\_ Name \_\_\_\_\_ Birth Date \_\_\_\_\_

Birth Place \_\_\_\_\_ Address \_\_\_\_\_

Tel \_\_\_\_\_ Cell \_\_\_\_\_ e-mail \_\_\_\_\_

Clinical Exam

Dentition Deciduous  Mixed  Permanent

Skeletal characteristics Class I  Class II  Class III

Dental class Class I  Class II  Class III

Maxillary contraction Anterior cross  Lateral Cross

Deepbite  Openbite  Overjet

Temporomandibular clicking or pain Yes  No

Requested Rx exams OPT  LatCeph  PA Ceph

ENT diagnosis

	YES	WHEN:	NO
TONSILLECTOMY	YES	WHEN:	NO
ADENOIDECTOMY	YES	WHEN:	NO
CRANIOFACIAL TRAUMA	YES		NO
SARAFACE	YES		NO
BREATHING DIFFICULTIES	YES		NO
FREQUENT RHINITIS	YES		NO
FREQUENT OTITIS	YES		NO
TONSILLITIS	YES		NO
PHARYNGITIS	YES		NO
OPEN MOUTH RESTING POSTURE	YES		NO
THUMB SUCKING/OTHER	YES		NO

FIG. 2 Clinical record.



with different health care providers that followed this group of patients during their growth phase (logopaedists, osteopathic doctors, allergologists).

- 2) Collection of intraoral and extraoral photos of the patients (Fig. 5, 6), impressions, ortopantomographs and lateral cephalograms.
- 3) Instructions were given to patients and their parents; motivated to maintain a proper hygiene.
- 4) Follow-up appointments were scheduled every 6–8 weeks, and the orthodontist established the duration of treatment based on the clinical results.
- 5) At the follow-up appointments, intraoral and extraoral photos were taken. Patients or guardians were asked to fill in a treatment progress questionnaire, in order to evaluate the response to the treatment (Table 1).  
This questionnaire is very important because it helps

clinicians to record data that can not be observed during the follow-up appointment (i.e. snoring, sleeping with mouth open, sleep apnoea, somnambulism, etc.).

**Results**

Froggy Mouth resulted effective in the correction of atypical swallowing. This appliance showed positive clinical results in resolving malocclusions such as open bite (Fig. 7), transverse palatal contraction, cross bite (Fig. 9) and deep bite (Fig. 10) in patients during their physiological growth phase. From the evaluation of the treatment progress questionnaire, it can be observed that the Froggy Mouth helped in resolving other issues such as snoring, drooling, sleep apnoea, and difficulty breathing through nose (Table 2). Extraoral photos (Fig. 11) show the change in the face, neck and shoulder

INFERIOR LIP SUCKING	YES	NO
SLEEPS WITH THE MOUTH OPEN	YES	NO
SNORING	YES	NO
EYE BAGS	YES	NO
NOCTURNAL SWEATING	YES	NO
DIFFICULTIES IN WAKING UP IN THE MORNING	YES	NO
NOCTURNAL ENURESIS	YES	NO
CHAPPED LIPS	YES	NO
NIGHTMARES	YES	NO
SLEEPWALKING	YES	NO
TALKS DURING SLEEP	YES	NO
FREQUENT NOCTURNAL WAKE UPS	YES	NO
SAVANA STAINS ON PILLOW	YES	NO
SLEEP APNEA	YES	NO
THE CHILD POSITIONS THE TONGUE FORWARD WHILE SPEAKS OR SWALLOWS	YES	NO
HYPERACTIVITY	YES	NO
TROUBLE CONCENTRATING	YES	NO

**SPEECH DIAGNOSIS**


**NEUROLOGICAL DIAGNOSIS**

CEREBROVASCULAR DISEASE	YES	NO
POSTURAL AND MUSCLE TONE DISTURBANCES	YES	NO
DYSTONIAS	YES	NO
HEADACHES	YES	NO

FIG. 3 Clinical record.

PROBLEMS DURING BIRTH (HYPOXIA)	YES	NO
MULTIPLE TCBS	YES	NO
OTHER	YES	NO

**ORTHOPAEDIC AND POSTURAL DIAGNOSIS**

TORTICOLLIS		
EVIDENT POSTURAL ASYMMETRIES		
FLAT HEAD SYNDROME		
ORTHOPAEDIC VISITS OR TREATMENTS		
IF YES, WHY?		
PHYSICAL THERAPY VISITS OR TREATMENTS		
IF YES, WHY?		
PSYCHOMOTOR VISITS OR TREATMENTS		
IF YES, WHY?		
OTHER		

**ALLERGIC DIAGNOSIS**


**ORTHODONTIC THERAPEUTIC PLAN**


**USE OF FROGGY MOUTH APPLIANCE**

- > AS UNIQUE APPLIANCE
- > AS SUPPORT IN ORTHOPHONIC RETRAINING
- > COADJUVANT IN THE ORTHODONTICTHERAPY

FIG. 4 Clinical record.

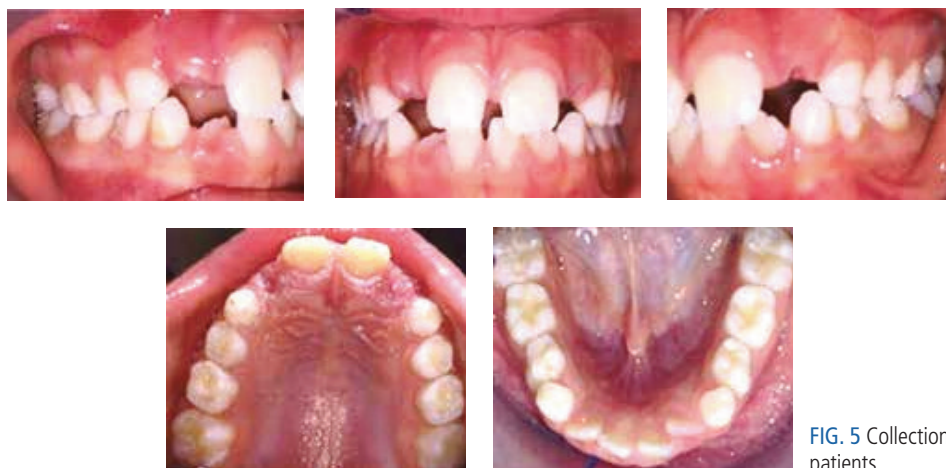

FIG. 5 Collection of intraoral photos of patients.

position immediately after wearing the device. These clinical results can point out a direct correlation between an altered contraction of perioral and masticatory musculature and

an asymmetrical contraction of cervical musculature, with TMJ and posture implications [Saccomanno et al., 2014; Ortu et al., 2018]. This requires a good cooperation with

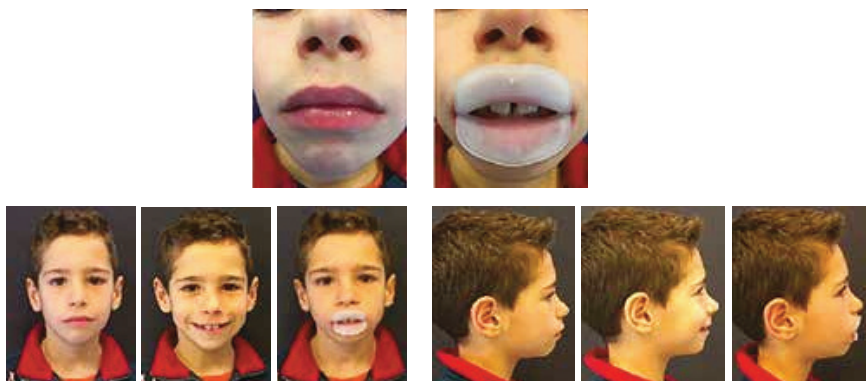

FIG. 6 Collection of extraoral photos of patients.

	FIRST CONTROL AT 3 MONTHS		SECOND CONTROL AT 6 MONTHS		THIRD CONTROL AT 9 MONTHS	
- THE CHILD REFERS EARACHE?	Yes	No	Yes	No	Yes	No
- KEEPS HAVING DIFFICULTIES BREATHING?	Yes	No	Yes	No	Yes	No
- STARTS WITH THE MOUTH OPEN DURING THE DAY?	Yes	No	Yes	No	Yes	No
- KEEPS SUCKING THE FINGER?	Yes	No	Yes	No	Yes	No
- KEEPS SUCKING THE PACIFIER?	Yes	No	Yes	No	Yes	No
- KEEPS SUCKING THE INFERIOR LIP?	Yes	No	Yes	No	Yes	No
- KEEPS SLEEPING WITH THE MOUTH OPEN?	Yes	No	Yes	No	Yes	No
- KEEPS SNORING?	Yes	No	Yes	No	Yes	No
- SHOWS EYE BAGS?	Yes	No	Yes	No	Yes	No
- KEEPS SWEATING AT NIGHT?	Yes	No	Yes	No	Yes	No
- HAS DIFFICULTIES IN WEARING LIP OR THE ARCHWIRE?	Yes	No	Yes	No	Yes	No
- HAS NOCTURNAL ENURESIS?	Yes	No	Yes	No	Yes	No
- HAS CHAPPED LIPS?	Yes	No	Yes	No	Yes	No
- REFERS NIGHTMARES?	Yes	No	Yes	No	Yes	No
- THE PATIENT SLEEPWALKS?	Yes	No	Yes	No	Yes	No

- PATIENT TALKS DURING SLEEP?	Yes	No	Yes	No	Yes	No
- PATIENT REFERS FREQUENT NOCTURNAL AWAKENINGS?	Yes	No	Yes	No	Yes	No
- YOU NOTE STAINS OF SALIVA ON THE PILLOW?	Yes	No	Yes	No	Yes	No
- THE PATIENT HAS NOCTURNAL APNEAS?	Yes	No	Yes	No	Yes	No
- THE PATIENT PUTS THE TONGUE BETWEEN THE ARCADES WHEN SPEAKING/SWALLOWING?	Yes	No	Yes	No	Yes	No
- THE PATIENT IS HYPERACTIVE?	Yes	No	Yes	No	Yes	No
- THE PATIENT HAS DIFFICULTIES IN CONCENTRATING?	Yes	No	Yes	No	Yes	No
- THE PATIENT REFERS MUSCLE TONE DISTURBANCES?	Yes	No	Yes	No	Yes	No
- THE PATIENT REFERS HEADACHES?	Yes	No	Yes	No	Yes	No

TABLE 1 - TABLE 2 In order to evaluate the response to the treatment, a treatment progress questionnaire was administered.

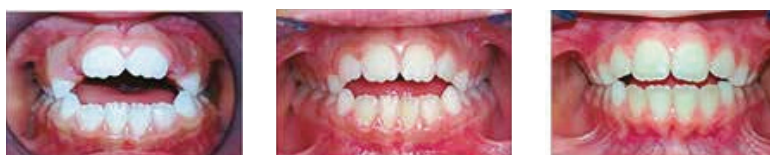

FIG. 7 Case 1 age 8, female, altered tongue posture, open bite, atypical swallowing Before (A), at 4 months (B), after 6 months (C).

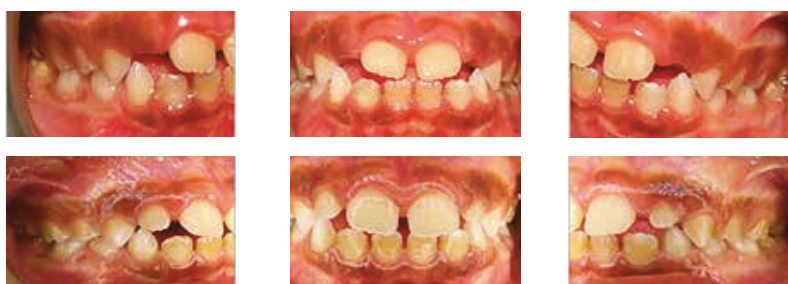

FIG. 8 Case 2 age 8, male, altered tongue posture, open bite, atypical swallowing. Before (A, B, C), at 6 months (D, E, F).

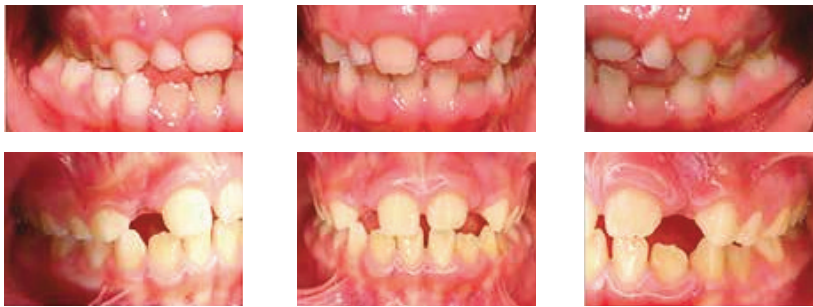

FIG. 9 Case 3 age 7, male, altered tongue posture, crossbite, atypical swallowing. Before (A, B, C), at 6 months (D, E, F).

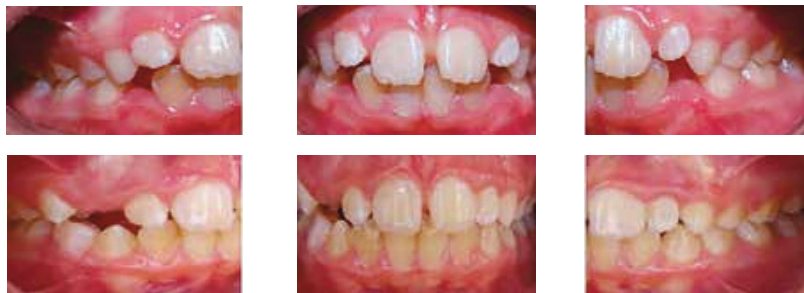

FIG. 10 Case 4 age 8, ternale, altered tongue posture, deepbite, atypical swallowing. Before (A, B, C), at 8 months (D, E, F).




FIG. 11 Extraoral photos showing the change in the face, neck and shoulder position after wearing the device.

the osteopath, to monitor and elaborate these early results [Otrria et al., 2018; Otrria et al., 2018; Otrria et al., 2018]. The device also requires less compliance from the patient (only 15 minutes per day) compared to traditional speech therapy alone and, as established by the studies of Kandel [2007], the results are more predictable and long-lasting.

### Conclusions

Clinical evidences indicate that the clinical protocol of Froggy Mouth is effective in the myofunctional correction of the atypical swallowing mechanism, providing the clinician a new therapeutic approach for atypical swallowing and dysfunctional deglutition in patients during their growth phase. However, it should be underscored that the concomitant speech therapy is crucial for faster and effective results. However, further scientific evidence should support these early results.

### References

› Bernardi S, Zeka K, Mummolo S, Marzo G, Continenza MA. Development of a new protocol: a macroscopic study of the tongue dorsal surface. *Int J Anatom Embriol* 2013; 118(2):24.

› Tecco S, Baldini A, Mummolo S, Marchetti E, Giuca MR, Marzo G, Gherlone EF. Frenulectomy of the tongue and the influence of rehabilitation exercises on the sEMG activity of masticatory muscles. *J Electromyogr Kinesiol* 2015; 25(4):619-628.

› Mummolo S, Ortu E, Necozone S, Monaco A, Marzo G. Relationship between mastication and cognitive function in elderly in L'Aquila. *Int J Clin Exp Med* 2014; 7(4):1040-6.

› Condò R, Costacurta M, Perugia C, Docimo R. Atypical deglutition: diagnosis and interceptive treatment. A clinical study. *Eur J Paediatr Dent* 2012; 13(3):209-14.

› Suárez C, Antonarakis GS, Pham D. Occlusal characteristics in subjects with or without the ability to roll the tongue. *Eur J Paediatr Dent* 2014; 15(2):147-150.

› Eichenberger M, Baumgartner S. The impact of rapid palatal expansion on children's general health: a literature review. *Eur J Paediatr Dent* 2014; 15(1):67-71.

› Mummolo S, Marchetti E, Albani F, Campanella V, Pugliese F, Di Martino S, Tecco S, Marzo G. Comparison between rapid and slow palatal expansion: evaluation of selected periodontal indices. *Head Face Med* 2014; 10:30.

› Giuca MR, Pasini M, Pagano A, Mummolo S, Vanni A. Longitudinal study on a rehabilitative model for correction of atypical swallowing. *Eur J Paediatr Dent* 2008; 9(4):170-4.

› Tecco S, Lacarbonara M, Dinoi MT, Gallusi G, Marchetti E, Mummolo S, Campanella V, Marzo G. The retrieval of unerupted teeth in pedodontics: two case reports. *J Med Case Rep* 2014; 8:334.

› Tecco S, Mummolo S, Marchetti E, Tetè S, Campanella V, Gatto R, Gallusi G, Tagliabue A, Marzo G. sEMG activity of masticatory, neck, and trunk muscles during the treatment of scoliosis with functional braces. A longitudinal controlled study. *J Electromyogr Kinesiol* 2011; 21(6):885-92.

› Maspero, C., et al. Atypical swallowing: a review. *Minerva Stomatol* 2014 63(6): 217-227.

› Mummolo S, Tieri M, Tecco S, Mattei A, Albani F, Giuca MR, Marzo G. Clinical evaluation of salivary indices and levels of *Streptococcus Mutans* and *Lactobacillus* in patients treated with Occlus-o-Guide. *Eur J Paediatr Dent* 2014; 15(4):367-70.

› Kandel E. *Alla ricerca della memoria. La storia di una nuova scienza della mente* 2007, Codice edizioni, Torino.

› Felus P. Dysfunctions linguale et dysmorphies Orthod Fr 2006; 77: 105-12

› Fellus P. Succion et déglutition Revue d'Orthopedie Dentofacial 2014; vol 48; 4 : 425-8

› Fellus P. De la succion-déglutition à la déglutition du subject denté Orthod Fr 2016; 87: 89-90

› Ortu E, Lacarbonara M, Cattaneo R, Marzo G, Gatto R, Monaco A. Electromyographic evaluation of a patient treated with extraoral traction: a case report. *Eur J Paediatr Dent* 2016; 17(2):123-128.

› Saccomanno S, Antonini G, D'Alatri L, D'Angeloantonio M, Fiorita A, Deli R. Case report of patients treated with an orthodontic and myofunctional protocol. *Eur J Paediatr Dent* 2014; 15(2):184-186.

› Ortu E, Pietropaoli D, Marchetti E, Marchilli N, Marzo G, Monaco A. Bruxism in children: use of the Functional Plane of Monaco (FPM). *Eur J Paediatr Dent* 2018; 19(4):287-294

› Otrria L, Candotto V, Guzzo F, Gargari M, Barlattani A. "Temporomandibular joint and related structures: anatomical and Histological aspects". *J Biol Regul Homeost Agents*. 2018 Jan-Feb;32(2 Suppl. 1):203-207.

› Otrria L, Lauritano D, Guzzo F, Gargari M, Barlattani A. "Anatomic relationship between temporomandibular joint and middle ear". *J Biol Regul Homeost Agents*. 2018 Jan-Feb;32(2 Suppl. 1):209-212.

› Otrria L, Candotto V, Guzzo F, Gargari M, Barlattani A. "TMJ's capsule histological and macroscopic study: relationship between ligamentous laxity and TMI dysfunctions". *J Biol Regul Homeost Agents*. 2018 Jan-Feb;32(2 Suppl. 1):213-216.